

EANM guidelines for ventilation/perfusion scintigraphy

Part 2. Algorithms and clinical considerations for diagnosis of pulmonary emboli with V/P_{SPECT} and MDCT

M. Bajc · J. B. Neilly · M. Miniati · C. Schuemichen ·
M. Meignan · B. Jonson

Published online: 24 July 2009
© EANM 2009

Abstract As emphasized in Part 1 of these guidelines, the diagnosis of pulmonary embolism (PE) is confirmed or refuted using ventilation/perfusion scintigraphy (V/P_{SCAN}) or multidetector computed tomography of the pulmonary arteries (MDCT). To reduce the costs, the risks associated with false-negative and false-positive diagnoses, and unnecessary radiation exposure, preimaging assessment of clinical probability is recommended. Diagnostic accuracy is approximately equal for

MDCT and planar V/P_{SCAN} and better for tomography (V/P_{SPECT}). V/P_{SPECT} is feasible in about 99% of patients, while MDCT is often contraindicated. As MDCT is more readily available, access to both techniques is vital for the diagnosis of PE. V/P_{SPECT} gives an effective radiation dose of 1.2–2 mSv. For V/P_{SPECT}, the effective dose is about 35–40% and the absorbed dose to the female breast 4% of the dose from MDCT performed with a dose-saving protocol. V/P_{SPECT} is recommended as a first-line procedure in patients with suspected PE. It is particularly favoured in young patients, especially females, during pregnancy, and for follow-up and research.

M. Bajc (✉) · B. Jonson
Department of Clinical Physiology, Lund University Hospital,
S-221 85 Lund, Sweden
e-mail: Marika.bajc@med.lu.se

B. Jonson
e-mail: bjorn.jonson@med.lu.se

J. B. Neilly
University Medical Unit & Nuclear Medicine,
Glasgow Royal Infirmary,
Glasgow G31 2ER, Scotland, UK
e-mail: jneilly@clinmed.gla.ac.uk

M. Miniati
Department of Medical and Surgical Critical Care,
University of Florence, Italy,
Viale Morgagni 85,
50134 Florence, Italy
e-mail: massimo.miniati@unifi.it

C. Schuemichen
University Hospital Rostock, Clinic for Nuclear Medicine,
Gertrudenplatz 1,
18057, Rostock, Germany
e-mail: carl.schuemichen@med.uni-rostock.de

M. Meignan
Department of Nuclear Medicine,
Centre Hospitalo Universitaire Henri Mondor, Université Paris 12,
94000 Créteil, France
e-mail: michel.meignan@hmn.aphp.fr

Keywords Pulmonary embolism · Radionuclide imaging ·
Ventilation perfusion scintigraphy ·
Single-photon emission computed tomography ·
X-ray computed tomography · Guidelines

Abbreviations

COPD	Chronic obstructive pulmonary disease
MAA	Macroaggregated human albumin
MDCT	Multidetector computed tomography of the pulmonary arteries
PA	Contrast-enhanced pulmonary angiography
PE	Pulmonary embolism
V/P _{PLANAR}	Ventilation/perfusion scintigraphy with planar imaging
V/P _{SCAN}	Ventilation/perfusion scintigraphy
V/P _{SPECT}	Ventilation/perfusion single photon emission computed tomography

Introduction and background

The primary objective of the Task Group was to develop guidelines for the use of ventilation/perfusion scintigraphy

for the diagnosis and follow up of PE. In the first part of the Guidelines, the principles, techniques and interpretation with a focus on V/P_{SPECT} were presented with respect to the diagnosis of PE and other diseases such as COPD, left heart failure and pneumonia [1]. The objectives of this second part were to define the importance of clinical probability together with objective imaging tests and to analyse the advantages and disadvantages of V/P_{SPECT} compared to MDCT.

Referral criteria and assessment of clinical probability

Diagnosis of PE

Knowledge of predisposing factors is a useful guide to the diagnosis, but as many as 26% to 47% of patients with a first diagnosis of venous thromboembolism have no recognizable risk factors for this disease [2]. The electrocardiograph may provide pointers to the presence of right ventricular overload such as S1, Q3, T3, right bundle branch block, right axis deviation and, in longstanding cases, P-pulmonale. The chest radiograph may provide evidence of atelectasis, raised hemidiaphragm, cardiomegaly, pulmonary infarction and Westmark's sign (vascular rarefaction) [3]. However, while these are pointers, they are not diagnostic of PE [4]. The chest radiograph is useful for alternative diagnoses such as pneumothorax, pneumonia, COPD, lung cancer or pulmonary fibrosis. Patients with PE may have arterial hypoxaemia and hypocapnia [4–6]. However, these signs are nonspecific and are also seen in patients without PE.

Assessment of the clinical probability of PE

The results of broad prospective studies lend support to the concept that clinical probability assessment is an important step in the diagnosis of PE [4, 7–11]. When considered individually, symptoms, signs, or common laboratory tests have limited diagnostic power. Jointly, however, they may provide accurate assessment of the clinical probability of PE.

Assessment of the clinical probability can be accomplished empirically or by means of a prediction rule. The latter is preferable over empirical assessment, especially for less experienced clinicians. In recent years, structured prediction models for PE have been developed with the very purpose of improving and easing the diagnostic approach [12–18].

The Canadian model introduced by Wells et al. [17] is the most frequently used prediction rule for suspected PE (Table 1). It includes seven variables of which three refer to well-recognized risk factors for PE. The model heavily depends on the subjective judgement as to whether an

Table 1 Wells' model

Predictor	Score
Prior PE or venous thromboembolism	1.5
Heart rate >100 beats per minute	1.5
Recent surgery or immobilization	1.5
Signs of venous thromboembolism	3.0
Alternative diagnosis less likely than PE	3.0
Haemoptysis	1.0
Cancer	1.0

alternative diagnosis is less likely than PE and, as such, it can hardly be standardized. The Wells' model seems better suited to rule out rather than to rule in the diagnosis of PE [1, 14], and its performance is likely to be better in clinical settings where the prevalence of the disease is expected to be low [19].

Recently, a more precise prediction model [1, 15] was introduced which rests on 16 variables including older age, risk factors, preexisting cardiopulmonary diseases, relevant clinical symptoms and signs, and the interpretation of the electrocardiogram (Table 2). The area under the receiver operating characteristic curve was 0.90 in the derivation sample ($n=1,100$), and 0.88 in the validation sample ($n=400$). In contrast to other prediction rules, the model includes variables that are negatively associated with PE. This gives the model greater flexibility, which may explain why it performs equally well in detecting and in ruling out PE. Also, instead of using a point-scale score proportional to the regression coefficients, typical of other approaches [13, 17, 18], the probability of PE is estimated directly from the algebraic sum of the regression coefficients. This allows prediction of the clinical probability as a continuous function. It estimates likelihood ratios for PE precisely. Its clinical value has been explored in a recent study [15]. To facilitate the applicability of the model in clinical settings, easy-to-use software is available for online computation of the clinical probability on a palm computer and mobile phone (<http://www.ifc.cnr.it/pisamodel>).

Combining clinical probability with objective testing for PE

Assessing the clinical probability of PE helps clinicians choose the most appropriate objective test for diagnosing or excluding PE (Fig. 1).

The measurement of D-dimer (a breakdown product of crosslinked fibrin clot) is widely used in the investigative work-up of patients with suspected venous thromboembolism [20]. Quantitative assay of D-dimer, based on a rapid ELISA method, has a high sensitivity (in the region of 95%) for venous thromboembolism [20]. Yet the test features a low specificity (40%) because D-dimer may be

Table 2 Clinical prediction model for PE (simplified Pisamodel)

Predictor	Coefficient
Age 57–67 years	0.80
Age 68–74 years	0.87
Age 75–95 years	1.14
Male sex	0.60
Prior cardiovascular disease	−0.51
Prior pulmonary disease	−0.89
History of venous thromboembolism	0.64
Immobilization (>3 days)	0.42
Sudden onset dyspnoea	2.00
Orthopnoea	−1.51
Chest pain	1.01
Haemoptysis	0.93
Fainting or syncope	0.66
Unilateral leg swelling suggestive of venous thromboembolism	0.80
Fever >38°C	−1.47
Wheezes	−1.20
Crackles	−0.61
ECG signs of acute cor pulmonale	1.96

raised in a number of conditions other than venous thromboembolism such as acute myocardial infarction, stroke, inflammation, active cancer, and pregnancy. The specificity falls with age and, in the elderly, may reach only 10% [20]. Accordingly, a negative quantitative D-dimer test has a high negative predictive value for venous thromboembolism. Results of outcome studies reveal that the risk of developing PE in patients with low clinical probability, who are untreated after a negative D-dimer test is <1% at 3 months after the initial evaluation [19, 20]. On the other hand, due to the low predictive value, a positive quantitative D-dimer test does not modify the pretest (clinical) probability and is, therefore, clinically useless. Recent evidence, however, suggests that very high D-dimer levels are associated with a fourfold increase in the likelihood of

PE [21]. It may be important in assessing the burden of thromboembolic disease [22] and may have prognostic significance [23, 24].

Clinical algorithm for investigation of patients with suspected PE

Stable patients

Based on the above, if the clinical likelihood of PE is low and the quantitative D-dimer is negative, a diagnosis of PE is unlikely and further investigations are not required (Fig. 1). If the clinical likelihood of PE is low and the quantitative D-dimer is positive, further investigations for a range of diagnoses including PE may be required, particularly if the D-dimer level is markedly elevated. If the clinical probability is other than low, it seems more appropriate to skip the D-dimer test and refer the patient directly to the appropriate imaging technique (Fig. 1). This may be V/P_{SCAN} or MDCT depending on the local availability, medical expertise, and the patient's clinical condition. V/P_{SCAN} has virtually no contraindications and yields a substantially lower radiation burden than MDCT. The latter is more widely and readily available.

Haemodynamically unstable PE

If the patient presents with severe hypotension or cardiogenic shock (Fig. 2), transthoracic echocardiography may stand as the first-line imaging technique. It allows detection of right heart dilatation and hypokinesis [25]. In rare circumstances, it may visualize emboli within the right heart cavities or main pulmonary artery [26]. Perfusion lung scintigraphy is an alternative option as it may quickly show multiple segmental or lobar perfusion defects that are typical of acute PE [8]. If an acute dissection of the thoracic aorta is suspected because of chest pain, MDCT may offer the opportunity to evaluate for this differential

Fig. 1 Diagnostic strategy in stable patients according to clinical probability of PE

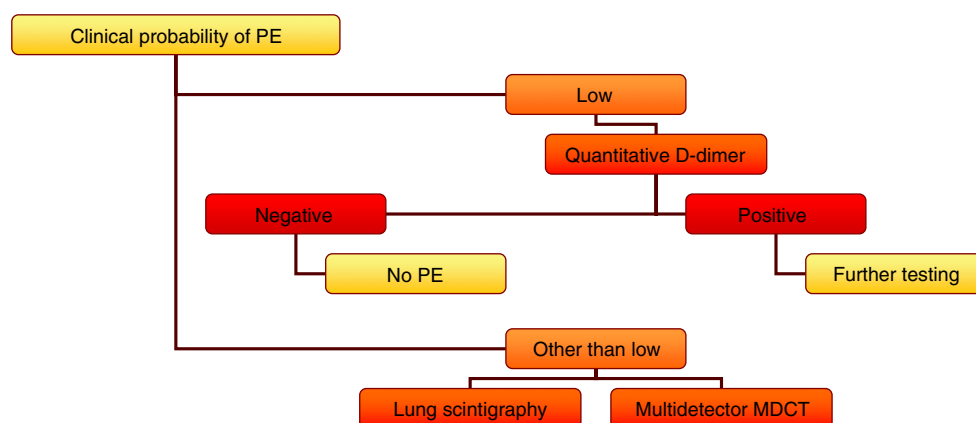
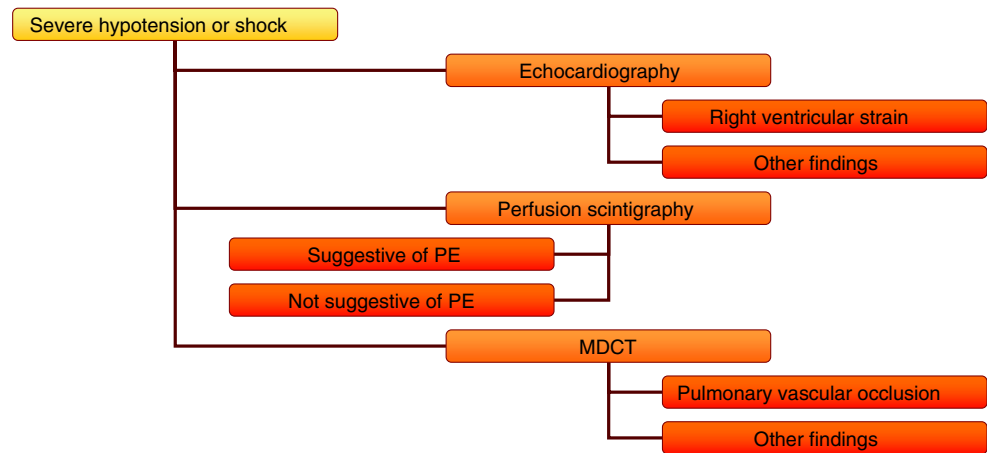


Fig. 2 Diagnostic strategy in patients with severe hypotension or shock



diagnosis. Given the need for haste in diagnosis and treatment of such patients, the diagnostic strategy employed at a particular institution must be adapted to the specific clinical situation and to the local circumstances.

When the initial examination suggests massive PE further action must be adapted to the clinical situation. Thrombolytic therapy might be given. If not already performed, a perfusion scan should be performed as soon as possible as a basis for further follow-up.

Imaging studies in PE

As clarified in Part 1 [1], the diagnosis of PE relies upon imaging tests, notably V/P_{SCAN} and MDCT. These techniques are discussed below with focus on the following:

- Accuracy for PE diagnosis
- Clinical feasibility with respect to contraindications and availability
- Radiation exposure
- Suitability for follow up and research
- Overall diagnostic strategies for good clinical practice

Diagnostic accuracy

MDCT is often recommended as the imaging test of first choice for the diagnosis of PE [27]. The evidence base for the use of MDCT as the principal imaging tool for the diagnosis of PE is not as robust as was generally thought. There is an emerging evidence base showing improved diagnostic accuracy for PE using V/P_{SPECT}. The following is a discussion of the merits of V/P_{SPECT} versus MDCT in the diagnosis of PE.

In many clinical studies, including recent ones, comparisons between V/P_{SCAN} and MDCT have been based upon obsolete scintigraphic techniques and interpretation criteria [7, 10]. In particular, PIOPED I found that 65% of scintigraphy studies were nondiagnostic. It has been shown

that a reduction in the proportion of nondiagnostic studies to 10% can be achieved even with V/P_{PLANAR} with adequate acquisition [28] and a holistic interpretation strategy [28, 29]. With V/P_{SPECT} and nonprobabilistic interpretation, this proportion is further reduced to below 3% [30–34]. Applying PISAPED criteria to material from PIOPED II the rate of nondiagnostic studies was 0% [35].

The lack of a satisfactory gold standard for the diagnosis of PE poses difficulties for the assessment of sensitivity, specificity and accuracy of all diagnostic methods for PE. The best available benchmark is an adequate follow-up of the patients for recurrence of PE or alternative diagnoses. The most rigorous study of MDCT in the diagnosis of PE is the PIOPED II study which used 4–16-slice MDCT [10]. This study showed a sensitivity for PE of 83% excluding nondiagnostic studies. This led to the observation that “The false negative rate of 17% for MDCT indicates the need for additional information to rule out PE” [36]. If nondiagnostic studies were included, the overall sensitivity fell to 78%. In the PIOPED II study the positive predictive value for a PE within a lobar pulmonary artery was 97% but fell to 68% and 25% in segmental and subsegmental pulmonary vessels, respectively.

After a negative single-slice CT study, PE occurred in 1.4% of patients in a meta-analysis of 4,637 patients [37]. After a negative PA study this was 1.6% [38], and after a negative MDCT study 1.5% ($n=318$). After a negative V/P_{SCAN}, the occurrence of PE during follow-up was 0.4% in a total of 1,877 patients [30, 39–41]. Freeman stated that the results of the PIOPED II study “do not clearly support the superiority of CT angiography over ventilation/perfusion scanning for the diagnosis of PE” [42]. Notably, this conclusion was based upon V/P_{PLANAR} and probabilistic interpretation. A direct comparison between V/P_{SPECT} and four-slice MDCT showed a higher sensitivity by V/P_{SPECT} [34]. In a recent retrospective study, Bajc et al. showed that V/P_{SPECT} had higher sensitivity, and specificity and fewer nondiagnostic studies than 16-slice CT [30]. Further prospective comparisons between up to date V/P_{SPECT} and

MDCT are needed. In reading of V/P_{SPECT} studies, low interobserver variability has been shown by a kappa value of 0.92 [31].

In Part 1 of these guidelines additional diagnoses found on V/P_{SPECT} include COPD, left heart failure and pneumonia [30]. MDCT provides valuable information about diagnoses other than PE, such as aortic aneurysm, tumour, pleural effusion and pneumonia.

Feasibility

PIOPED II illustrates well the limited clinical utility of MDCT. In 50% of eligible patients, MDCT could not be performed because of kidney failure, critical illness, recent myocardial infarction, ventilator support and allergy to the contrast agent. Furthermore, 6% of performed MDCT studies were of insufficient quality for conclusive interpretation. In about 1% complications including allergy, contrast agent extravasation and increased creatinine level were observed. By contrast, V/P_{SPECT} has no contraindications and was performed in 99% of patients referred in the study by Bajc et al. [30]. Complications do not occur, and the rate of technically suboptimal studies is close to zero. It is possible to accommodate patients who are mechanically ventilated by connecting a nebulizer to the inspiratory ventilator line. In rare cases, when V/P_{SPECT} cannot be performed, V/P_{PLANAR} remains an alternative.

Availability

MDCT is available in nearly all medical centres and community hospitals. Service is often available around the clock seven days a week. V/P_{SPECT} is available in many fewer hospitals and seldom on a 24-hour basis. For this reason the choice between MDCT and scintigraphy is often determined by availability. In hospitals with nuclear medicine facilities the choice of imaging may depend on when scintigraphy is available.

Radiation dose

Image quality can be enhanced by allowing higher radiation doses when using X-ray techniques and in isotope studies. Obviously, any clinical routine should be based upon procedures offering a radiation dose as low as possible but with image quality that is proven appropriate with respect to a particular diagnosis.

V/P_{SPECT}

Radiation doses for V/P_{SPECT} can be quite closely estimated according to the International Commission for Radiation Protection (ICRP). A systematic analysis of imaging

protocols for V/P_{SPECT} has shown that 25–30 MBq of ^{99m}Tc-aerosol for ventilation and 100–120 MBq of ^{99m}Tc-MAA for perfusion in combination with proper collimation and time for imaging renders optimal V/P_{SPECT} images for the diagnosis of PE [43]. The protocol has documented efficacy for the diagnosis of PE and also for left heart failure [30, 44]. Using these activities the effective radiation dose from V/P_{SPECT} is 1.2–2 mSv (Table 1 in Part 1) [1]. The absorbed dose to the female breast is estimated as 0.8 mGy [45, 46]. During the first trimester, the data of Hurwitz et al. applied to the recommended dose for perfusion study (50 MBq) gives a fetal absorbed dose of 0.1–0.2 mGy [47].

MDCT

At centres with identical multislice scanners, the estimation of absorbed doses may vary by a factor of 7 depending on the CT protocol and other variables [48]. In general, MDCT results in higher direct radiation and scatter doses than single-slice CT [49–51]. This may change with the introduction of radiation-saving protocols (see below). In the literature, estimations of radiation dose from MDCT vary within wide limits. According to ICRP [52], the average effective dose for 4–16-detector MDCT is 5.4 mSv. Notably, this information was based on computed rather than measured dose data. Hurwitz et al. reported for a current adult PE protocol with 64-detector MDCT a measured effective dose of 19.9±1.38 mSv [53]. These authors point out that the actual measured dose is about 50% higher than the computed dose. The absorbed dose to the breasts was 35–42 mGy. Absorbed radiation dose to the breast for a single-slice CT study was 20–50 mGy and 30–50% greater with a four-slice CT [54].

In a very recent study, Hurwitz et al. [55] studied radiation dose-saving protocols. Phantoms of women were exposed to MDCT protocols with automatic current modulation, lower tube voltage and bismuth shields over the chest. For the medium sized woman with automatic current modulation, the breast doses at 140 kVp were 62 mGy and 33 mGy when bismuth shields were added. At 120 kVp the doses were 44 mGy without shields and 20 mGy with shields. Some limitations of the study were discussed. No phantom with significant subcutaneous fat was studied. The authors were not able to directly assess the effect of increased noise for the diagnosis of PE. Dose-saving protocols are promising.

The fetal radiation dose from a 16-slice MDCT study was recently analysed by Hurwitz et al. [47]. During the first trimester the absorbed fetal dose was estimated as 0.24–0.66 mGy and significantly higher later during gestation. Recent studies have shown that MDCT is often technically suboptimal during pregnancy. The rate of nondiagnostic MDCT studies was 27.5% during pregnancy, versus 7.5% in

nonpregnant women [56]. In 10 out of 16 pregnant women, contrast opacification within the pulmonary arteries was borderline or insufficient for diagnosis [57]. A reason for poor diagnostic outcome of MDCT in pregnancy is probably increased cardiac output and plasma volume.

V/P_{SPECT} and MDCT

Based upon data from ICRP reports, the effective dose for V/P_{SPECT} with the recommended protocol is about 35–40% of the dose from MDCT [45, 46, 52]. The dose to the female breast for V/P_{SPECT} is only 4% of the dose from MDCT with full dose-saving means according to Hurwitz et al. [55]. This may have particular importance in pregnant women with proliferating breast tissue [58]. During the first trimester of pregnancy the fetal dose from MDCT is greater than or equivalent to that of V/P_{SCAN} [47]. The advantage of V/P_{SPECT} increases after the first trimester.

Follow-up

Follow-up of PE using imaging is essential to:

- Assess the effect of therapy
- Differentiate between new and old PE on suspicion of PE recurrence
- Investigate physical incapacity after PE

In symptomatic patients treated for PE, the outcome varies, from total resolution of thrombi within days, to permanent vascular occlusion. In spite of this, most patients are treated with heparin/warfarin for 6 months. Some patients have a tendency to recurrent episodes of PE. Without initial and follow-up images, it is often impossible to differentiate between old and new PE. In patients with low resolution of thrombus and, particularly in those with recurrent emboli, life-long therapy is indicated. In this group of patients physical capacity is often reduced. Follow-up imaging may explain symptoms caused by unresolved PE [59] or by other diseases, e.g. COPD or heart failure.

Patients treated with thrombolysis for massive PE suffer the risk of bleeding, but also dangers related to unresolved PE. Immediate control gives objective information about the need for repeated thrombolysis.

Symptomatic patients with small emboli are diagnosed by sensitive methods, particularly V/P_{SPECT}. The natural history and the value of treatment in this group of patients are not fully elucidated. Follow-up is indicated to individualize therapy, as further discussed under [Suitability for Research](#).

V/P_{SPECT} meets the requirements for methods used in follow-up including:

- Applicability in all patients
- Low radiation dose

- High sensitivity to allow estimation of resolution of even small emboli and occurrence of new ones

Recommendation

V/P_{SPECT} is ideally suited for use in the follow-up of PE because small and large emboli are recognized so that regression or progression of thrombotic disease can be studied in detail. Furthermore, the low radiation exposure allows repeated studies. It can be applied in all patients. Obviously, using the same method for diagnosis and for follow-up has great advantages. Perfusion-only scintigraphy may be chosen for control during the initial phase of treatment.

Suitability for research

Knowledge about the natural history of PE is limited. There is a need to study alternative strategies for PE therapy, with respect to therapy duration and choice of drugs in different categories of patients. It is likely that shorter and less-dangerous treatment protocols might be preferable in selected patients. The low incidence of symptomatic PE at follow-up after negative imaging tests might be explained by the fact that most emboli are nonocclusive and cause no harm. The lung is an efficient filter for emboli, which may be a common and natural phenomenon. It has in most people a high capacity to resolve thrombi fast, regardless of initial PE extension. This has been shown by a 44% decrease in perfusion defects after only 5 days of low molecular heparin treatment, which in itself has no thrombolytic effect [60]. Very short treatment, or even no treatment, might be the preferred strategy in selected patients.

The demands on an imaging technique for research into PE and its treatment are in principle the same as for clinical follow-up. However, in research, the motivation to use nontraumatic procedures associated with the lowest possible risks is for ethical reasons even stronger.

The issue of small emboli is particularly important. We still have limited knowledge about the need for treatment. Only the most sensitive method, i.e. V/P_{SPECT}, can be used to clarify such problems.

Recommendation

V/P_{SPECT} is recommended for research into the natural course and treatment of PE.

Diagnostic algorithms

PE, when suspected, must be confirmed or refuted to avoid the risks of both over and under treatment. This requires

imaging tests. Only optimal techniques are recommended. These are MDCT and V/P_{SPECT} with holistic interpretation.

The imaging modality used will depend on availability. While MDCT is more readily available, it is contraindicated in a substantial numbers of patients as shown in the PIOPED II study [10]. At present, V/P_{SPECT} is rarely available over 24 hours 7 days a week. Accordingly, these two methods should be available at least in tertiary hospital centres because both are crucial for adequate algorithms for the diagnosis of PE. In each centre, the algorithm applied for the diagnosis of PE must be based upon local circumstances, and first and foremost upon the availability of V/P_{SPECT} and MDCT.

- MDCT is in general more readily available than V/P_{SPECT}
- V/P_{SPECT} carries no risk associated with contrast agent injection
- V/P_{SPECT} gives a much lower radiation burden
- V/P_{SPECT} yields a lower rate of nondiagnostic reports
- V/P_{SPECT} has higher sensitivity at similar specificity
- V/P_{SPECT} allows better estimation of PE extension based upon the functional impact of PE

It follows that, when available, V/P_{SPECT} offers considerable advantages over other imaging techniques for the diagnosis of PE. These advantages include its high

sensitivity and specificity for the diagnosis of PE, its lower and predictable radiation burden, and its suitability for follow-up of patients with PE and for research into the natural history of PE. On the basis of the recent methodological development of V/P_{SPECT} and documentation of its performance, it is recommended that this method is made more generally available. Under ideal circumstances either V/P_{PLANAR} or V/P_{SPECT} can be performed and interpreted within 1 hour of referral [43, 61]. It is acknowledged that MDCT is widely and readily available and that it will take some time for V/P_{SPECT} to reach parity with MDCT. Accordingly, diagnostic algorithms should be based upon V/P_{SPECT} and MDCT. From centres with no availability of V/P_{SPECT}, patients may be referred for V/P_{SPECT} studies elsewhere, when indicated.

The knowledge on V/P_{SPECT} is available. As there are only a few centres using this technique and particularly its holistic interpretation, there is a need for systematic teaching and training. This is a responsibility of the Nuclear Medicine discipline.

According to good clinical practice, V/P_{SPECT} should be widely implemented and its performance assessed using clinical audit.

In the algorithm illustrated in Fig. 3, the entry point is based on the clinical probability of PE, as illustrated in Fig. 1.

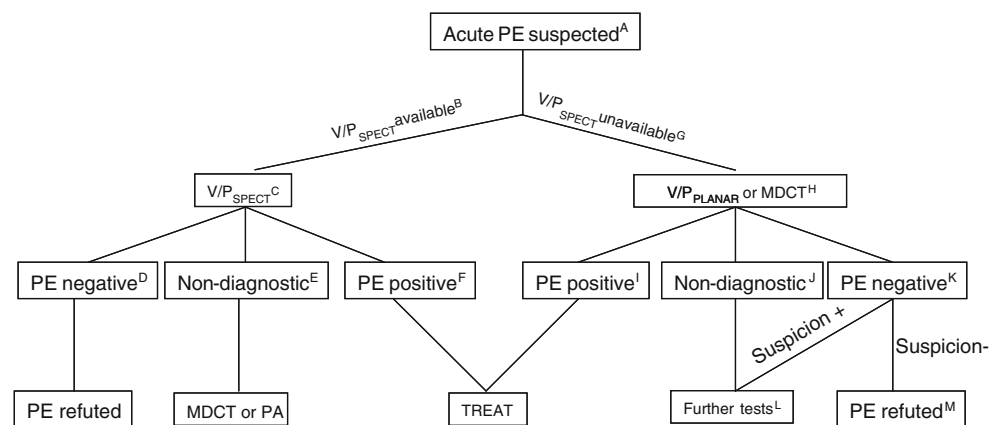


Fig. 3 Algorithm for diagnostic imaging of patients with clinically suspected acute PE. *A* Clinical suspicion derived from Prediction Models. *B* V/P_{SPECT} is the procedure of choice; if V/P_{SPECT} is not immediately available, consider treatment (heparin) depending on clinical circumstances. *C* V/P_{SPECT} is interpreted according to the holistic principle in which clinical pretest probability is a part. *D* A normal V/P_{SPECT} is observed in the majority of cases and excludes PE in almost 100%. *E* Few cases are non-diagnostic; further diagnostic procedures are recommended, such as MDCT or in special cases PA. *F* V/P_{SPECT} is the most sensitive method; positive findings should lead to treatment in nearly all cases; research is urgently needed into the treatment of very low grade of mismatch indicating PE. *G* V/P_{PLANAR}, holistically interpreted, or MDCT is recommended when V/P_{SPECT} is not readily available. *H* V/P_{PLANAR} is preferred on the basis of its

better negative predictive value, no contraindications and much lower radiation exposure. *I* If V/P_{PLANAR} or MDCT is positive treatment is warranted in most cases; in the context of a low pretest probability, a positive V/P_{PLANAR} or a MDCT without direct visualization of the embolism is an indication for further investigation. *J* When V/P_{PLANAR} or MDCT is negative, further tests are indicated. *K* When V/P_{PLANAR} or MDCT is negative and the clinical suspicion of PE persists, further tests for PE should be performed. *L* In this context, V/P_{SPECT} is the preferred additional test; if not available, MDCT should be followed by V/P_{PLANAR} or vice versa; PA remains an alternative if the diagnosis remains unclear. *M* A normal V/P_{PLANAR} excludes PE; where the V/P_{PLANAR} is abnormal but negative for PE, or the MDCT is negative, PE is ruled out in those patients in whom clinical suspicion of PE is low

Table 3 Types of evidence

Level	Type of evidence
Ia	Obtained from meta-analysis of randomized controlled trials
Ib	Obtained from at least one randomized controlled trial
IIa	Obtained from at least one well-designed controlled study without randomization
IIb	Obtained from at least one other type of well-designed quasiexperimental study
III	Obtained from well-designed nonexperimental descriptive studies, such as comparative studies, correlation studies and case-control studies
IV	Expert opinion

Based on AHCPR, 1992

Table 4 Key to grades of recommendations

Grade	Evidence level	Description
A	Ia, Ib	Requires at least one randomized controlled trial as part of the body of literature of overall good quality and consistency addressing the specific recommendation
B	IIa, IIb, III	Requires availability of well-conducted clinical studies, but no randomized clinical trials on the topic of recommendation
C	IV	Requires evidence from expert committee reports or opinions and/or clinical experience of respected authorities. Indicates absence of directly applicable studies of good quality

Based on AHCPR, 1994

Table 5 Key recommendations for the clinical assessment of suspected PE

Recommendation	Level	Grade
Clinical probability should be used to select patients for imaging studies in suspected PE	Ib	A
In patients with a low clinical probability of PE and a normal quantitative D-dimer, further imaging tests for PE are not normally required	IIa	B
Patients requiring imaging tests for suspected PE should undergo these investigations within 24 h of referral	IV	C
In patients with suspected massive PE, the diagnosis should be established with haste allowing appropriate treatment to commence. In these circumstances echocardiography, MDCT or V/P _{SCAN} imaging may assist with diagnosis depending on availability	IV	C
In patients with suspected pulmonary embolism awaiting confirmatory tests, treatment with heparin should be commenced without delay unless contraindicated	Ib	A

Table 6 Key recommendations for the use of ventilation scintigraphy in PE imaging

Recommendation	Level	Grade
A ventilation study should be done to support the perfusion scan in all patients with suspected PE, except during the first trimester of pregnancy	Ib	A
^{81m} Kr is the radioactive gas of choice, when available, being a true gas and allowing simultaneous acquisition with the perfusion images	III	B
Radiolabelled aerosols with documented particle size and distribution pattern are recommended on the basis of their widespread availability	III	B
^{99m} Tc-Technegas is the agent of choice in the presence of obstructive lung disease	III	B
^{99m} Tc-DTPA aerosol is the agent of choice when ^{99m} Tc-Technegas is not available	III	B

Table 7 Key recommendations for the investigation of regional pulmonary perfusion in PE diagnosis

Recommendation	Level	Grade
^{99m}Tc -MAA is the agent recommended for perfusion scintigraphy	IIa	B
The minimum number of particles is 60,000, but ideally the number should be about 400,000	III	B
In infants/children and in patients with known pulmonary hypertension the number of particles should be reduced	III	B
The vial should be gently shaken before injection and blood withdrawal into the syringe before injection should be avoided	IV	C
Injection should be performed under normal tidal breathing in the supine position	IV	C

Table 8 Key recommendations for imaging protocols using lung scintigraphy in PE diagnosis

Recommendation	Level	Grade
For PE imaging a 1-day V/P study should be performed, starting with ventilation, followed by perfusion, aiming for an activity ratio of 1:4	IIb	B
V/P _{SPECT} is preferred to V/P _{PLANAR} when using V/P _{SCAN} for PE diagnosis	IIb	B
When using planar imaging, a minimum of six views is recommended	IIb	B
In pregnancy, particularly during the first trimester, a 2-day protocol starting with a perfusion-only scan followed if necessary by a second day ventilation study	IV	C

Table 9 Key recommendations for the interpretation and reporting of V/P scans in PE diagnosis

Recommendation	Level	Grade
Probabilistic criteria such as that used in the PIOPED studies are flawed and should not be used for the interpretation of the V/P _{SCAN}	IV	C
No PE should be reported if the perfusion scan is normal as defined by the anatomic boundaries of the lungs	Ia	A
No PE should be reported if perfusion defects are matched or reverse mismatched	IIb	B
No PE should be reported if perfusion defects do not conform to vascular anatomy, i.e. pulmonary, lobar, segmental or subsegmental in pattern	IIb	B
PE should be reported if there is at least one segmental or two subsegmental perfusion defects	IIb	B
The lung scan report should include mention of all relevant findings particularly when this may have a bearing on further patient management	III	B
The report of the lung scan with recommendations for further management should be communicated without delay to the referring clinical team	IV	C
V/P _{SPECT} is ideally suited for use in the follow-up of PE because small and large emboli can be assessed for regression or progression	IV	C
V/P _{SPECT} is a useful tool for research about the natural course and treatment of PE	IV	C

Key to evidence statements and grades of recommendations

The definition of types of evidence and the grading of recommendations used in the guidelines follow those of the Agency for Healthcare Research and Quality (formerly Agency for Health Care Policy and Research, AHCPR), as set out in Tables 3 and 4. The key recommendations highlighted by the Guideline Development Group are set out in Tables 5 to 9.

Acknowledgments We would like to thank the EANM Dosimetry Committee for the contribution and Medan Rehani, chair of the Task Group on Radiation Protection IAEA for sharing his knowledge and for fruitful discussions.

Conflicts of interest None.

References

- Bajc M, Neilly B, Miniati M, Schuemichen C, Meignan M, Jonson B. EANM guidelines for ventilation/perfusion scintigraphy, Part 1. Pulmonary imaging with ventilation/perfusion single photon emission tomography. *Eur J Nucl Med Mol Imaging* 2009; 2009. Submitted.
- White RH. The epidemiology of venous thromboembolism. *Circulation* 2003;107:14–8. doi:10.1161/01.CIR.0000078468.11849.66.
- Westmark N. On the roentgen diagnosis of lung embolism. *Acta Radiol* 1938;19:358–72.
- Miniati M, Prediletto R, Formichi B, Marini C, Di Ricco G, Tonelli L, et al. Accuracy of clinical assessment in the diagnosis of pulmonary embolism. *Am J Respir Crit Care Med* 1999;159:864–71.
- Miniati M, Monti S, Bottai M. A structured clinical model for predicting the probability of pulmonary embolism. *Am J Med* 2003;114:173–9. doi:10.1016/S0002-9343(02) 01478-X.
- Tapson VF. Acute pulmonary embolism. *N Engl J Med* 2008;358:1037–52. doi:10.1056/NEJMra072753.
- The PIOPED Investigators. Value of the ventilation/perfusion scan in acute pulmonary embolism. Results of the prospective investigation of pulmonary embolism diagnosis (PIOPED). *JAMA* 1990;263:2753–9. doi:10.1001/jama.263.
- Miniati M, Pistolesi M, Marini C, Di Ricco G, Formichi B, Prediletto R, et al. Value of perfusion lung scan in the diagnosis of pulmonary embolism: results of the Prospective Investigative Study of Acute Pulmonary Embolism Diagnosis (PISA-PED). *Am J Respir Crit Care Med* 1996;154:1387–93.
- Roy PM, Colombet I, Durieux P, Chatellier G, Sors H, Meyer G. Systematic review and meta-analysis of strategies for the diagnosis of suspected pulmonary embolism. *BMJ* 2005;331:259. doi:10.1136/bmj.331.7511.259.
- Stein PD, Fowler SE, Goodman LR, Gottschalk A, Hales CA, Hull RD, et al. Multidetector computed tomography for acute pulmonary embolism. *N Engl J Med* 2006;354:2317–27. doi:10.1056/NEJMoa052367.
- van Belle A, Buller HR, Huisman MV, Huisman PM, Kaasjager K, Kamphuisen PW, et al. Effectiveness of managing suspected pulmonary embolism using an algorithm combining clinical probability, D-dimer testing, and computed tomography. *JAMA* 2006;295:172–9. doi:10.1001/jama.295.2.172.
- Labas P, Ohradka B, Vladimir J, Cambal M. The home treatment of deep vein thrombosis with low molecular weight heparin, forced mobilisation and compression. *Int Angiol* 2000;19:303–7.
- Le Gal G, Righini M, Roy PM, Sanchez O, Aujesky D, Bounameaux H, et al. Prediction of pulmonary embolism in the emergency department: the revised Geneva score. *Ann Intern Med* 2006;144:165–71.
- Miniati M, Bottai M, Monti S. Comparison of 3 clinical models for predicting the probability of pulmonary embolism. *Medicine* 2005;84:107–14. doi:10.1097/01.md.0000158793.32512.37.
- Miniati M, Bottai M, Monti S, Salvadori M, Serasini L, Passera M. Simple and accurate prediction of the clinical probability of pulmonary embolism. *Am J Respir Crit Care Med* 2008;178:290–4. doi:10.1164/rccm.200802-207OC.
- Miniati M, Monti S, Bauleo C, Scoscia E, Tonelli L, Dainelli A, et al. A diagnostic strategy for pulmonary embolism based on standardised pretest probability and perfusion lung scanning: a management study. *Eur J Nucl Med Mol Imaging* 2003;30:1450–6. doi:10.1007/s00259-003-1253-7.
- Wells PS, Anderson DR, Rodger M, Ginsberg JS, Kearon C, Gent M, et al. Derivation of a simple clinical model to categorize patients probability of pulmonary embolism: increasing the models utility with the SimpliRED D-dimer. *Thromb Haemost* 2000;83:416–20.
- Wicki J, Perneger TV, Junod AF, Bounameaux H, Perrier A. Assessing clinical probability of pulmonary embolism in the emergency ward: a simple score. *Arch Intern Med* 2001;161:92–7. doi:10.1001/archinte.161.1.92.
- Wells PS, Anderson DR, Rodger M, Stiell I, Dreyer JF, Barnes D, et al. Excluding pulmonary embolism at the bedside without diagnostic imaging: management of patients with suspected pulmonary embolism presenting to the emergency department by using a simple clinical model and d-dimer. *Ann Intern Med* 2001;135:98–107.
- Stein PD, Hull RD, Patel KC, Olson RE, Ghali WA, Brant R, et al. D-dimer for the exclusion of acute venous thrombosis and pulmonary embolism: a systematic review. *Ann Intern Med* 2004;140:589–602.
- Tick LW, Nijkeuter M, Kramer MH, Hovens MM, Buller HR, Leebeek FW, et al. High D-dimer levels increase the likelihood of pulmonary embolism. *J Intern Med* 2008;264:195–200. doi:10.1111/j.1365-2796.2008.01972.x.
- Goldin Y, Berliner S, Rogowski O, Pasowski O, Serov J, Halpern P, et al. Correlated expression of D-dimer concentrations with thrombotic burden in acute pulmonary embolism. *Blood Coagul Fibrinolysis* 2008;19:153–8. doi:10.1097/MBC.0b013e3282f544db.
- Ljungqvist M, Soderberg M, Moritz P, Ahlgren A, Larfars G. Evaluation of Wells score and repeated D-dimer in diagnosing venous thromboembolism. *Eur J Intern Med* 2008;19:285–8. doi:10.1016/j.ejim.2007.08.007.
- Wolf SJ, McCubbin TR, Nordenholz KE, Naviaux NW, Haukoos JS. Assessment of the pulmonary embolism rule-out criteria rule for evaluation of suspected pulmonary embolism in the emergency department. *Am J Emerg Med* 2008;26:181–5. doi:10.1016/j.ajem.2007.04.026.
- Goldhaber SZ, Elliott CG. Acute pulmonary embolism: part I: epidemiology, pathophysiology, and diagnosis. *Circulation* 2003;108:2726–9. doi:10.1161/01.CIR.0000097829.89204.0C.
- Goldhaber SZ, Haire WD, Feldstein ML, Miller M, Toltzis R, Smith JL, et al. Alteplase versus heparin in acute pulmonary embolism: randomised trial assessing right-ventricular function and pulmonary perfusion. *Lancet* 1993;341:507–11. doi:10.1016/0140-6736(93) 90274-K.

27. British Thoracic Society Standards of Care Committee Pulmonary Embolism Guideline Development Group. British Thoracic Society guidelines for the management of suspected acute pulmonary embolism. *Thorax* 2003;58:470–83. doi:10.1136/thorax.58.6.470.
28. Barghouth G, Yersin B, Boubaker A, Doenz F, Schnyder P, Delaloye AB. Combination of clinical and V/Q scan assessment for the diagnosis of pulmonary embolism: a 2-year outcome prospective study. *Eur J Nucl Med* 2000;27:1280–5. doi:10.1007/s002590000284.
29. Bajc M, Albrechtsson U, Olsson CG, Olsson B, Jonson B. Comparison of ventilation/perfusion scintigraphy and helical CT for diagnosis of pulmonary embolism; strategy using clinical data and ancillary findings. *Clin Physiol Funct Imaging* 2002;22:392–7. doi:10.1046/j.1475-097X.2002.00448.x.
30. Bajc M, Olsson B, Palmer J, Jonson B. Ventilation/perfusion SPECT for diagnostics of pulmonary embolism in clinical practice. *J Intern Med* 2008;264:379–87. doi:10.1111/j.1365-2796.2008.01980.x.
31. Leblanc M, Leveillee F, Turcotte E. Prospective evaluation of the negative predictive value of V/Q SPECT using 99mTc-Technegas. *Nucl Med Commun* 2007;28:667–72. doi:10.1097/MNM.0b013e32827a8e99.
32. Lemb M, Pohlabein H. Pulmonary thromboembolism: a retrospective study on the examination of 991 patients by ventilation/perfusion SPECT using Technegas. *Nucl Med (Stuttg)* 2001;40:179–86.
33. Reinartz P, Schirp U, Zimny M, Sabri O, Nowak B, Schaefer W, et al. Optimizing ventilation-perfusion lung scintigraphy: parting with planar imaging. *Nucl Med (Stuttg)* 2001;40:38–43.
34. Reinartz P, Wildberger JE, Schaefer W, Nowak B, Mahnen AH, Buell U. Tomographic imaging in the diagnosis of pulmonary embolism: a comparison between V/Q lung scintigraphy in SPECT technique and multislice spiral CT. *J Nucl Med* 2004;45:1501–8.
35. Sostman HD, Miniati M, Gottschalk A, Matta F, Stein PD, Pistolesi M. Sensitivity and specificity of perfusion scintigraphy combined with chest radiography for acute pulmonary embolism in PLOPED II. *J Nucl Med* 2008;49:1741–8. doi:10.2967/jnumed.108.052217.
36. Perrier A, Bounameaux H. Accuracy or outcome in suspected pulmonary embolism. *N Engl J Med* 2006;354:2383–5. doi:10.1056/NEJMe068076.
37. Moores LK, Jackson WL Jr, Shorr AF, Jackson JL. Meta-analysis: outcomes in patients with suspected pulmonary embolism managed with computed tomographic pulmonary angiography. *Ann Intern Med* 2004;141:866–74.
38. Henry JW, Relyea B, Stein PD. Continuing risk of thromboemboli among patients with normal pulmonary angiograms. *Chest* 1995;107:1375–8. doi:10.1378/chest.107.5.1375.
39. Henry JW, Stein PD, Gottschalk A, Raskob GE. Pulmonary embolism among patients with a nearly normal ventilation/perfusion lung scan. *Chest* 1996;110:395–8. doi:10.1378/chest.110.2.395.
40. Hull RD, Raskob GE, Coates G, Panju AA. Clinical validity of a normal perfusion lung scan in patients with suspected pulmonary embolism. *Chest* 1990;97:23–6. doi:10.1378/chest.97.1.23.
41. van Beek EJ, Kuyser PM, Schenk BE, Brandjes DP, ten Cate JW, Buller HR. A normal perfusion lung scan in patients with clinically suspected pulmonary embolism. Frequency and clinical validity. *Chest* 1995;108:170–3. doi:10.1378/chest.108.1.170.
42. Freeman LM. Don't bury the V/Q scan: it's as good as multidetector CT angiograms with a lot less radiation exposure. *J Nucl Med* 2008;49:5–8. doi:10.2967/jnumed.107.048066.
43. Palmer J, Bitzen U, Jonson B, Bajc M. Comprehensive ventilation/perfusion SPECT. *J Nucl Med* 2001;42:1288–94.
44. Jogi J, Palmer J, Jonson B, Bajc M. Heart failure diagnostics based on ventilation/perfusion single photon emission computed tomography pattern and quantitative perfusion gradients. *Nucl Med Commun* 2008;29:666–73. doi:10.1097/MNM.0b013e328302cd26.
45. ICRP. Radiation dose to patients from radiopharmaceuticals, publication 53. Oxford, New York: ICRP; 1988. p. 121.
46. ICRP. Radiation dose to patients from radiopharmaceuticals (addendum 2 to ICRP 53). *Ann ICRP* 1998;28:1–126.
47. Hurwitz LM, Yoshizumi T, Reiman RE, Goodman PC, Paulson EK, Frush DP, et al. Radiation dose to the fetus from body MDCT during early gestation. *AJR Am J Roentgenol* 2006;186:871–6. doi:10.2214/AJR.04.1915.
48. Koller CJ, Eatough JP, Bettridge A. Variations in radiation dose between the same model of multislice CT scanner at different hospitals. *Br J Radiol* 2003;76:798–802. doi:10.1259/bjr/33117342.
49. Burrage JW, Causer DA. Comparison of scatter doses from a multislice and a single slice CT scanner. *Australas Phys Eng Sci Med* 2006;29:257–9.
50. Huda W, Vance A. Patient radiation doses from adult and pediatric CT. *AJR Am J Roentgenol* 2007;188:540–6. doi:10.2214/AJR.06.0101.
51. Paul JF, Abada HT. Strategies for reduction of radiation dose in cardiac multislice CT. *Eur Radiol* 2007;17:2028–37. doi:10.1007/s00330-007-0584-3.
52. Valentin J; International Commission on Radiation Protection. Managing patient dose in multi-detector computed tomography (MDCT). ICRP Publication 102. *Ann ICRP* 2007;37:1–79.
53. Hurwitz LM, Reiman RE, Yoshizumi TT, Goodman PC, Toncheva G, Nguyen G, et al. Radiation dose from contemporary cardiothoracic multidetector CT protocols with an anthropomorphic female phantom: implications for cancer induction. *Radiology* 2007;245:742–50. doi:10.1148/radiol.2453062046.
54. Parker MS, Hui FK, Camacho MA, Chung JK, Broga DW, Sethi NN. Female breast radiation exposure during CT pulmonary angiography. *AJR Am J Roentgenol* 2005;185:1228–33. doi:10.2214/AJR.04.0770.
55. Hurwitz LM, Yoshizumi TT, Goodman PC, Nelson RC, Toncheva G, Nguyen GB, et al. Radiation dose savings for adult pulmonary embolus 64-MDCT using bismuth breast shields, lower peak kilovoltage, and automatic tube current modulation. *AJR Am J Roentgenol* 2009;192:244–53. doi:10.2214/AJR.08.1066.
56. U-King-Im JM, Freeman SJ, Boylan T, Cheow HK. Quality of CT pulmonary angiography for suspected pulmonary embolus in pregnancy. *Eur Radiol* 2008;18:2709–15.
57. Andreou AK, Curtin JJ, Wilde S, Clark A. Does pregnancy affect vascular enhancement in patients undergoing CT pulmonary angiography? *Eur Radiol* 2008;18:2716–22.
58. Schaefer-Prokop C, Prokop M. CTPA for the diagnosis of acute pulmonary embolism during pregnancy. *Eur Radiol* 2008;18:2705–8.
59. Miniati M, Monti S, Bottai M, Scoscia E, Bauleo C, Tonelli L, et al. Survival and restoration of pulmonary perfusion in a long-term follow-up of patients after acute pulmonary embolism. *Medicine* 2006;85:253–62. doi:10.1097/01.md.0000236952.87590.c8.
60. Olsson CG, Bitzen U, Olsson B, Magnusson P, Carlsson MS, Jonson B, et al. Outpatient tinzaparin therapy in pulmonary embolism quantified with ventilation/perfusion scintigraphy. *Med Sci Monit* 2006;12:PI9–13.
61. Tagil K, Evander E, Wollmer P, Palmer J, Jonson B. Efficient lung scintigraphy. *Clin Physiol* 2000;20:95–100. doi:10.1046/j.1365-2281.2000.00232.x.